Bird's Eye Diagram

Label the diagram below.

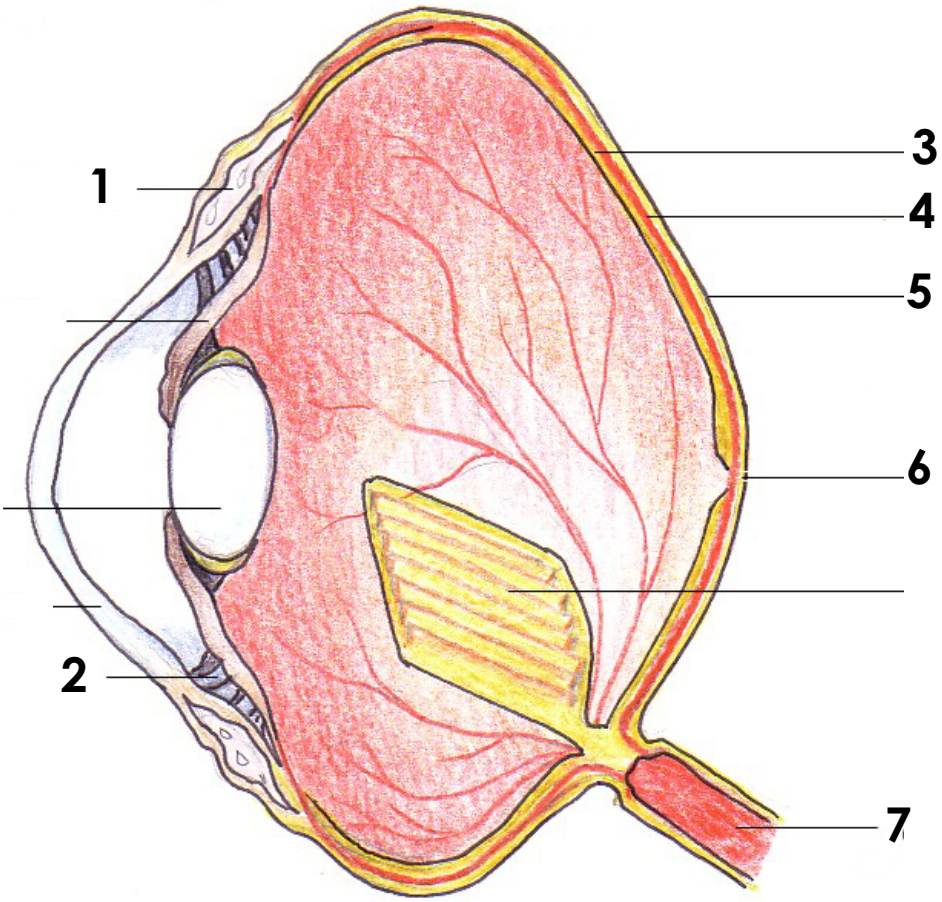

source: Jimfbleak (wikipedia)

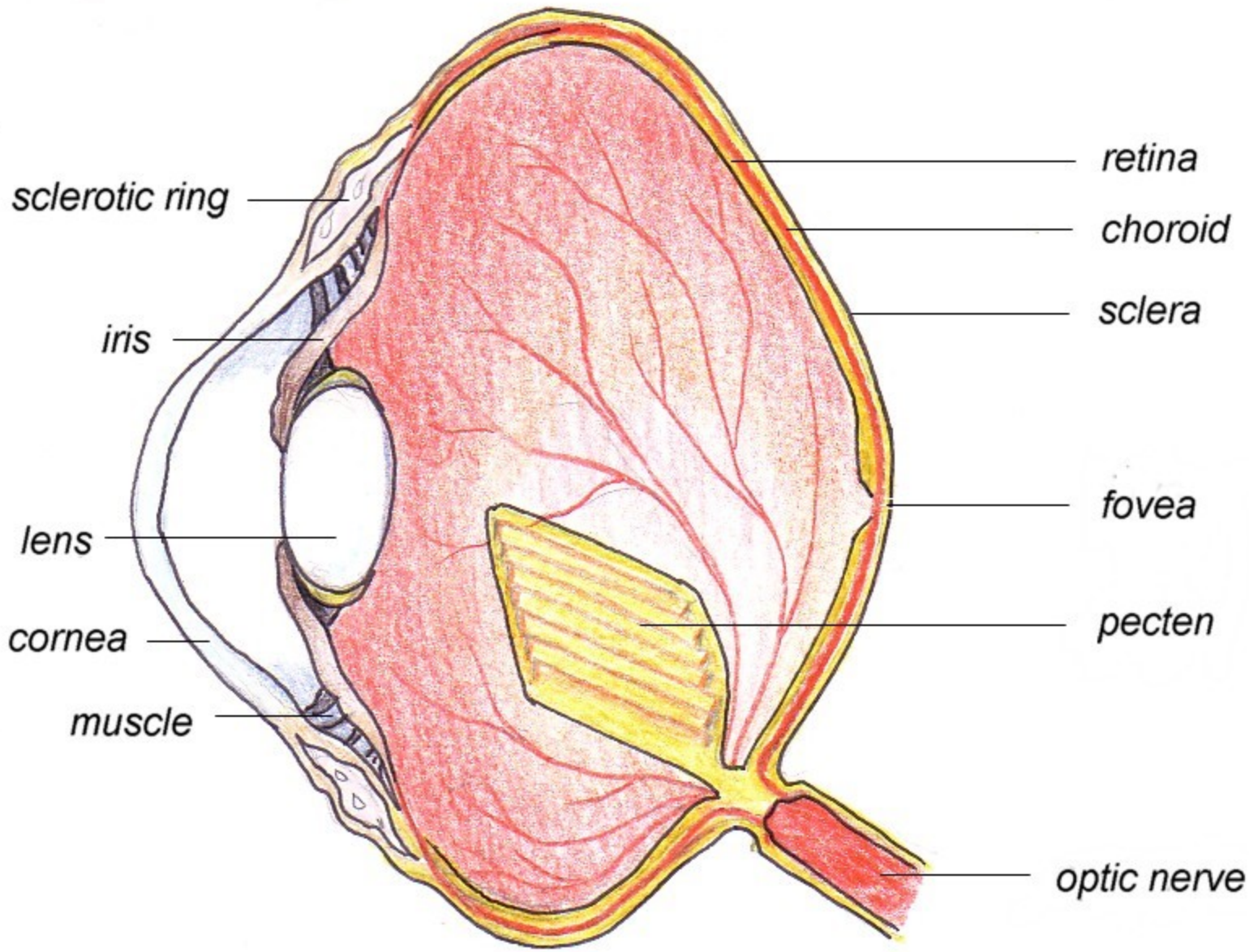
sclerotic ring
iris
lens
cornea
muscle
retina
choroid
sclera
fovea
pecten
optic nerve